

Impacts of Traditional Organometallic Interventions on Chronic Uterine Fibroids: A Case Report

Sohail Mulla^{1,*}, Bharat Rathi¹, Anita Wanjari¹, Klita Pereira²

¹Department of Rasashastra Evam Bhaishajya Kalpana, Mahatma Gandhi Ayurved College Hospital and Research Centre, Wardha, Maharashtra, INDIA.

²Department of Balrog, Mahatma Gandhi Ayurved College Hospital and Research Centre, Wardha, Maharashtra, INDIA.

ABSTRACT

Uterine fibroids are commonly seen benign tumours, leading to reproductive health disorders amongst abnormal bleeding, pelvic discomfort, and infertility. Surgery, including hysterectomy, or myomectomy has conventionally been the primary treatment, with considerable risks and a substantial economic burden. However, non-surgical approaches have been explored throughout history. This study presents a case of a 52-year-old woman with chronic uterine fibroids and associated Symptoms, including abnormal bleeding and severe burning sensations, which were successfully Resolved using traditional organometallic formulations. The patient, after developing symptoms Post-COVID vaccination, sought alternative treatment and was prescribed a combination of Indian classical organometallic formulations, including *Rasa Sindoor*, *Tamra Bhasma*, *Trivanga Bhasma*, and *Punarnavasava*. Within three months, the patient's condition significantly improved. Menstrual regularity was restored, bleeding ceased, and the burning sensation subsided. Follow-up imaging showed reduction in fibroid size. Biochemical investigations found within normal ranges, indicating safety and efficacy of the treatment. This case highlights the potential of *Ayurvedic* and traditional therapies as viable alternatives to surgery in managing uterine fibroids. However, the use of organometallic formulations, while effective, poses safety concerns due to the potential nephrotoxic effects of prolonged heavy metal exposure. Further research is necessary to explore the long-term safety and efficacy of such treatments.

Keywords: Dysmenorrhea, Uterine Fibroids, Traditional medicine, Ayurveda.

Correspondence:

Dr. Sohail D. Mulla

Department of Rasashastra Evam
Bhaishajya Kalpana, Mahatma Gandhi
Ayurved College Hospital and Research
Centre, Wardha, Maharashtra, INDIA.
Email: sohailm07@rediffmail.com

Received: 28-02-2025;

Revised: 08-04-2025;

Accepted: 18-06-2025.

INTRODUCTION

Uterine Fibroids are the most commonly seen benign growths that develop in various areas of the uterus, influenced by local growth factors and sex hormones like estrogen and progesterone. These prevalent tumors lead to considerable health issues for women and are the leading cause of hysterectomy procedures globally. Uterine myomas lead to various reproductive issues, including heavy or irregular bleeding, pelvic discomfort, infertility, and complications during pregnancy like miscarriage and preterm labor. Surgery has long been the preferred treatment for uterine leiomyomas, typically involving either a hysterectomy or myomectomy. Although these are invasive methods, with association of health risks and usually time consuming processes with potential economic burdens, they contributes to a significant economic burden on healthcare systems, costing around \$2.2 billion annually in the United States alone.^[1]

However, non-surgical resolving of the condition is fairly possible, as attempted by physicians dating back centuries, ensuring complete reversal of the condition with non-invasive methods.^[2]

Rasashastra is the indivisible branch of *Ayurveda* in which pharmaceutical preparations of herbal and organometallic formulations can be seen from historic times of iatrochemistry. Such traditional formulations are still in practice in today's era with significant results. In this study, we are reporting a case of surgery-advised chronic uterine fibroids and its associated complaints which were completely resolved by interventions of traditional organometallic compounds.

CASE PRESENTATION

Patient Information

A 52-year-old female patient consulted us with complaints of severe uterine bleeding per vagina and irregularities in menses associated with a burning sensation all over the body since last three years. The burning sensation was extreme enough, to relieve patient had to sleep on the floor every day.



ScienScript

DOI: 10.5530/ajbls.20251482

Copyright Information :

Copyright Author (s) 2025 Distributed under
Creative Commons CC-BY 4.0

Publishing Partner : ScienScript Digital, [www.scienscript.com.sg]

On asking about the history of the condition, it revealed that the complaints were first started three years ago after the injection of the first dose of ChAdOx1 nCoV-19 Coronavirus Vaccine (Recombinant). On the same day, multiple onsets of fever were noted. A high fever pattern was seen not subsiding. After being treated with NSAIDs on the advice of a local physician, the fever subsided in a week but the burning sensation all over the body persisted. After an interval of a few days, the patient noticed irregularities in her menstrual cycle, menses were lasting for about a month, and extremely severe bleeding per vagina was observed. A USG scan of the Abdomen and Pelvis, followed by advice of a local physician, did not report any abnormal impressions but abnormal uterine bleeding continued. Fed up with the irritation, after a few days patient consulted another physician, scan was followed, USG screening this time turned out certain concerning impressions regarding the condition of the Uterus:

a) 13x7 mm Small Subserosal Fibroid in the Anterior wall of the Fundus of the Uterus

By the same physician, the patient was treated with anti-fibrinolytic medications, resulting in menstruation being completely stopped for 2-3 months. No normal occurrence of menses was noted. After completing the course of the medication, retained the condition. This time, bleeding was seen in higher frequencies and mass concentrations than ever before. She again consulted the Physician, Scan was repeated as advised, portrayed following (See Figure 1) impressions:

a) Grade I Fatty Liver

b) 17x16 mm Fibroid with calcification in the anterior wall of the fundus of the Uterus.

c) 13x13 mm Fibroid in the Superior wall of the fundus of Uterus.

As the condition was seen deteriorating with a poor prognosis. Prior diagnosed small subserosal fibroid was seen growing in larger size by this time. The occurrence of another fibroid was seen accumulating on the Superior wall. The possible risk of the over mutations could not be neglected. The patient was still having severe abnormal bleeding conditions along with a severe burning sensation all over the body. Physicians advised the patient for the surgical management i.e. hysterectomy without any further delay. She was unsure about the Hysterectomy. Also, her husband was not willing to go for her hysterectomy by any means. Now patient approached us in extreme misery, with complaints as mentioned earlier.

Clinical Findings

On physical examination no any significant abnormalities were noted. Also, no any signs of Pallor, Edema, Cyanosis, Clubbing, Icterus or Lymphadenopathy were found. Per abdomen was seen soft. All vitals were normal. No symptoms of chest pain, giddiness, or sweating was observed. *Trividha Pareeksha* (examining triads)

denoted *Karsha* (emaciation), loss of *Prabha* (skin lustre), *Kharata* (dryness of skin). Patient was seen very worried about abnormal bleeding, also *Sarvanga Daha* (burning sensation all over body) was seen.

Timeline

The patient began experiencing health issues after receiving the ChAdOx1 nCoV-19 vaccine on March 16, 2021, including fever and a persistent burning sensation throughout her body. Over the following months, she also faced irregular and extremely prolonged menstrual cycles, with severe vaginal bleeding. A September 2022 ultrasound showed no abnormalities, but the bleeding continued. In April 2023, a new ultrasound revealed a small fibroid in the uterus, and she was treated with anti-fibrinolytic medications, which temporarily stopped her menstruation. However, after completing the treatment, her symptoms returned, with increased frequency and severity of bleeding. Subsequent ultrasounds in July 2023 and September 2024 showed growth of fibroids, including a calcified fibroid and the appearance of a new one. Due to deteriorating condition and ongoing symptoms, physicians recommended a hysterectomy, but the patient was not willing, and her husband opposed the procedure. She consulted us on October 2024.

Diagnostic assessment

All haematological findings were normal except Hb which was 9.2mg/dL. Urine analysis was normal shown no sign of diabetes. ECG portrayed NSR. USG imaging results were referred. Primary Diagnosis was made as Uterine Fibroids. Diagnosis as per *Ayurveda* was considered as *Vataja Raktapradara* (irregular uterine bleed) in association with *Raktaja Gulma* (uterine tumour).

Therapeutic Interventions

The patient was prescribed the medications as follows (See Table 1).

Follow-up and outcomes

By the end of the first month to the middle of the second month, the severe bleeding disorder of the patient completely stopped, indeed natural cycle of the menses was regained lasting for a normal period. The burning sensation subsided. After three months of the medications, Biochemical investigations were performed which shown the most values within normal range (See Table 2). USG scan for the Abdomen and Pelvis of the patient was repeated. Reporting the impressions as follow (See Figure 2).

a) Grade I fatty Liver

b) 3 mm Calculus in the middle calyx of the left Kidney.

c) 14x9 mm Fibroid with calcification in the anterior wall of the Fundus of Uterus.

Table 1: Complete Medication Plan.

Sl. No.	For First Month:	For Second Month:	For Third Month:	Duration:	ROA:
1	<i>Rasa Sindoor</i> (42 mg)+ <i>Tamra Bhasma</i> (84 mg)+ <i>Punarnavasava</i> (1-2 tsp)	<i>Rasa Sindoor</i> (42 mg) <i>Trivanga Bhasma</i> (84 mg)+ <i>Punarnavasava</i> (1-2 tsp)	<i>Rasa Sindoor</i> (42 mg)+ <i>Trivanga Bhasma</i> (84 mg)+ <i>Punarnavasava</i> (1-2 tsp)	OD	Oral
2	<i>Punarnavasava</i> (1-2 tsp)	<i>Punarnavasava</i> (1-2 tsp)	<i>Punarnavasava</i> (1-2 tsp)	HS	Oral

OD- Omnie Die (Once a day), HS- Hora Somni (Before bedtime), TSP-Teaspoons

Table 2: Biochemical Investigations.

Investigations:	Observed Value:	Unit:	Normal Range:
Haemoglobin	10.6	gms%	11.5-16
W.B.C. Count	10900	cells/cumm	4000-11000
R.B.C Count	4.63	millions/uL	4.5-5.5
Pack Cell Volume	36.3	%	40-54
MCV	78.4	fL	76-94
MCH	22.9	Pg	27-34
MCHC	29.2	g/dL	32-37
RDW CV	16.0	%	11.0-16.0
RDW SD	43.6	fL	35-56
Neutrophils	55	%	40-70
Lymphocytes	40	%	20-45
Esinophils	04	%	0-6
Monocytes	01	%	2-10
Basophils	00	%	0-1
Platelet Count	455000	%	150000-450000
ESR	15	At the end of 1 Hr	0-20
Investigations:	Observed Value:	Unit:	Normal Range:
Total Bilirubin	0.90	mg/dL	0-1.0
Direct Bilirubin	0.10	mg/dL	0-0.3
Indirect Bilirubin	0.8	mg/dL	0-0.8
S.G.O.T	38	IU/L	5-40
S.G.P.T	30	IU/L	5-35
S. Alk. Phosphate	38	IU/L	50-140
Investigations:	Observed Value:	Unit:	Normal Range:
Blood Urea	28	mg/dL	15-45
Blood Urea Nitrogen	13.08	mg/dL	5-21
Serun Creatinine	1.10	mg/dL	0.4-1.5

d) 13x13 mm Fibroid in the Superior wall of the Fundus of Uterus.

DISCUSSION

Exploratory trails for non-surgical alternatives for multiple chronic physical conditions dwelling into historic times were superior aim of iatrochemistry and physicians associated with it. Surgery, an invasive treatment method for most of the times is, recovery time consuming, possessing economic burden and may

associated with possible health risks for an individual. In above reported case, interventions of oral medications have shown us significant results in subsiding chronic conditions and associated symptoms, observing shrinkage pattern in fibroids.

Some recent studies conducted around globe have already reported possible association of Corona Virus Vaccine in irregularities of the menstrual cycle in the women. But in most of the cases such conditions were resolved within months.^[3-9]

Menstrual changes among females were noted in variety of vaccinations.^[10] Differences were noted in length and flow of menstrual cycle in vaccinated females. People who receive two doses of the vaccine in one cycle seem to experience a longer, though temporary, change in their menstrual cycle length.^[11]

Fibroids are benign neoplasms that develop from the smooth muscle tissue of the uterus (myometrium) and their growth is influenced by the hormones estrogen and progesterone.^[12] In a study conducted among two cohorts, delayed menstruation was not observed in vaccinated group which was intervened by hormonal contraceptives. Which played a protective role for delayed cycles, suggesting COVID-19 vaccinations could delay menstrual cycle which may be mediated by ovarian hormones.^[13] Although, no direct association of Vaccinations with developing Uterine fibroids is known so far.

Anti fibrinolytic therapy is conventional treatment for Fibrosis, although it leading to hyper-coagulability is serious concerns among clinicians. The risks of such medication for causing bleeding or thrombotic events are well-known. Considering *Rakta Sthambaka* (anti-fibrinolytic) medicines are one of the causative factors for *Raktaja Gulma* (uterine fibroid) has described in *Charaka Samhita*, Indian classical texture amongst the primarily literatures of *Ayurveda*.

The trace elements Selenium (Se) and Zinc (Zn) are known to play a significant role in enhancing a strong immune response to vaccination. Copper (Cu), on the other hand, is a crucial component of copper-containing proteins that provide structural stability and redox activity. It also acts as a cofactor in various enzymatic reactions. Copper and copper-dependent enzymes are involved in numerous essential biological processes, including

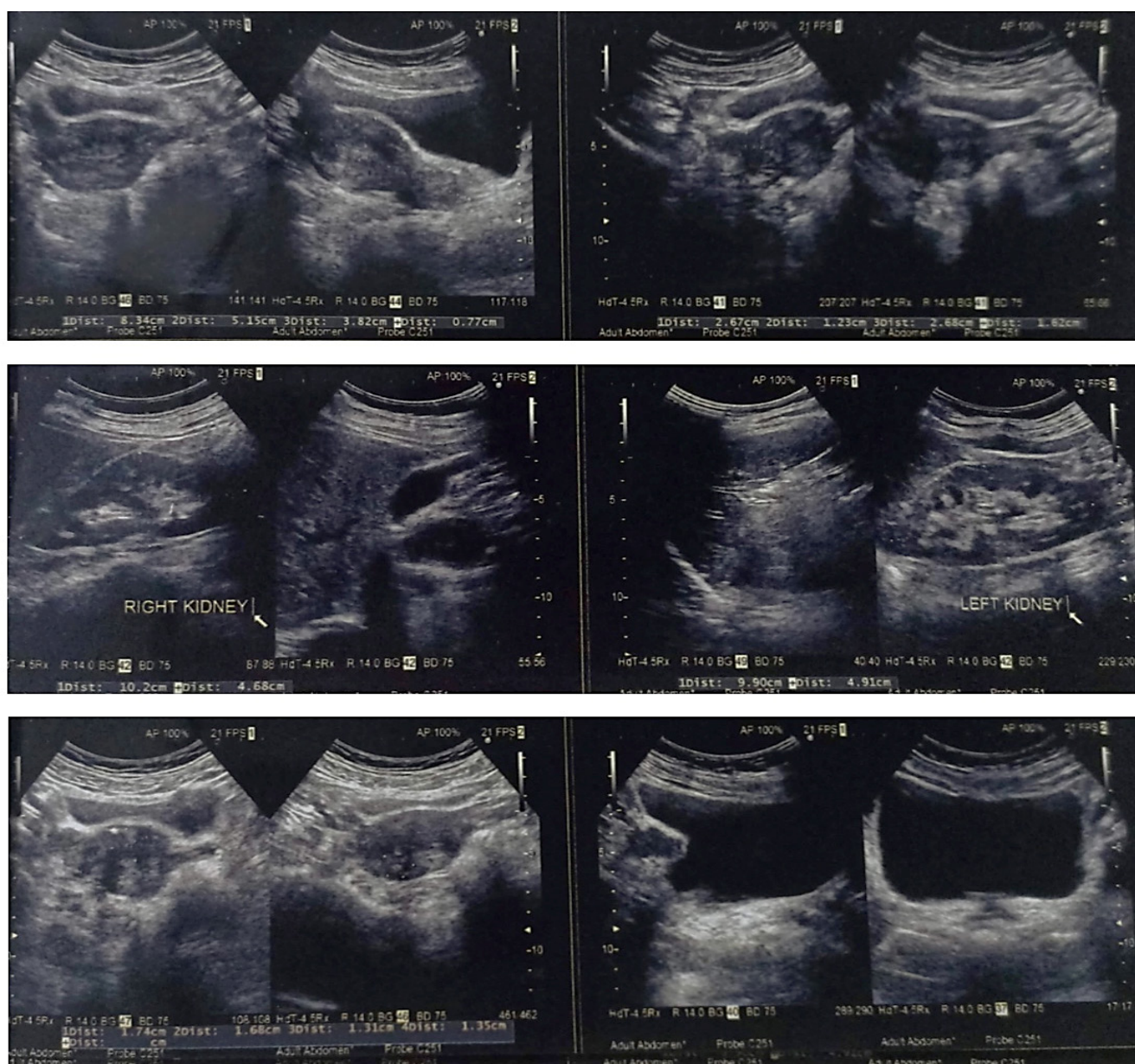


Figure 1: Real-time ultrasound sonography of abdomen and pelvis pre treatment.

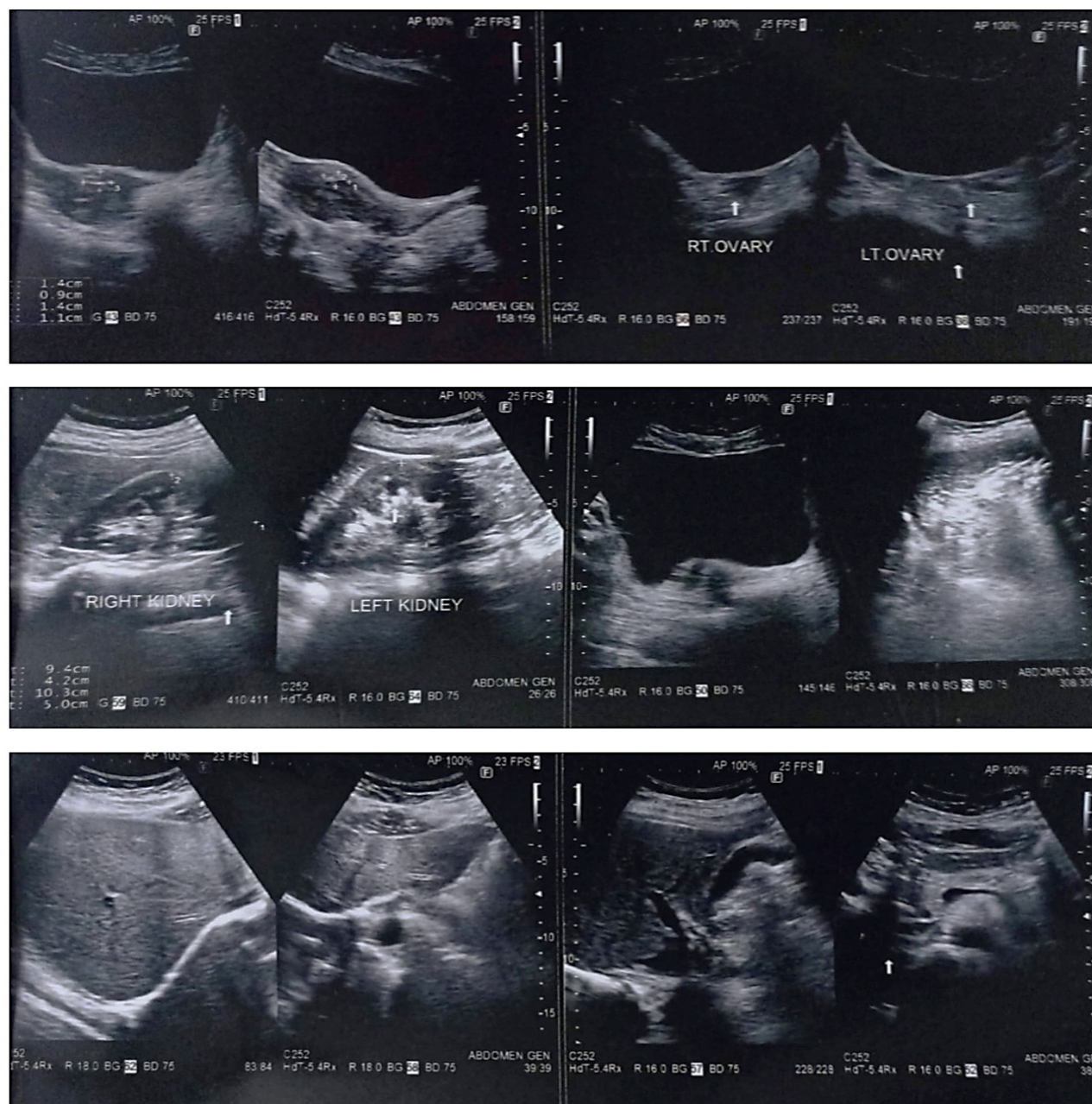

Figure 2: Real-time ultrasound sonography of abdomen and pelvis post treatment.

development, metabolism, and adaptation, significantly influencing immune system function and immune cell activity.^[14] Copper containing traditional organometallic formulation, *Tamra Bhasma*, has been used for centuries for *Rasayana* (rejuvenation) purposes. Zinc is being used in *Trivanga Bhasma*, Zinc predominantly has shown significant improvements in gynecological conditions. In a study of 66 individuals, consumption of Zinc supplements at therapeutic doses has shown significant relief in severity of dysmenorrhea.^[15]

Boerhavia diffusa has referred as *Punarnava* in Sanskrit means as regeneration of life or rejuvenator. Promising anti-inflammatory activity of *Boerhavia diffusa* has noted *in vivo*.^[16] *Rasa Sindoor*, the indigenous mercurial preparation which is being used from

ages of ancient iatrochemistry practices. Organomercurials, like thimerosal, have been used clinically in humans from ancient ages. Thimerosal is capable of crossing the blood-brain barrier, allowing it to reach effective concentrations for treating glioblastoma multiforme. The study findings indicated that both TmHg and EtHg promoted oxidative damage and induced cell death, primarily through apoptosis, resulting in a marked decrease in mouse glioblastoma GL261 cell viability. Both TmHg and EtHg have seen inducing apoptotic cell death at low concentrations.^[17]

Limitations of these interventions which we found, that most of the organometallic formulations mentioned above possess heavy metals in nanoparticle form. Hence, they always possess risks of prolonged Consumption. The biochemical investigations after

Table 3: Biochemical Investigations.

Blood Elemental Investigation:	Observed Value:	Unit:	Biological Ref. Interval:
Aluminium	22.3	ug/L	<30
Antimony	0.11	ug/L	<3.5
Arsenic	2.69	ug/L	<5
Barium	2.46	ug/L	<30
Beryllium	0.02	ug/L	<4
Bismuth	3.8	ug/L	<30
Cadmium	1.35	ug/L	<1.5
Caesium	1.7	ug/L	<5
Chromium	21.3	ug/L	<30
Cobalt	0.57	ug/L	<4
Lead	17	ug/L	<25
Manganese	19.54	ug/L	7.10-20
Mercury	1.71	ug/L	<5
Molybdenum	2.25	ug/L	0.70-4.0
Nickel	0.49	ug/L	<15
Selenium	122.82	ug/L	60-240
Silver	0.15	ug/L	<4
Strontium	22.4	ug/L	8-38
Thallium	0.06	ug/L	<1
Tin	0.26	ug/L	<2
Uranium	0.21	ug/L	<1
Vanadium	0.6	ug/L	<0.8

treatment have reported the most observed values within normal range, which may conclude safer interventions of such traditional organometallic formulations. Although, after three months of interventions of these traditional formulations seen to occur renal calculus in respective patient.

CONCLUSION

Corona Vaccine-induced thrombosis is well known to the world, some studies also reported disorders of the Menstrual cycle among vaccinated females. But there are no any evidences of Fibrosis induced by the Vaccine. Excessive use of anti-fibrinolytic drugs might be one among the causes of *Raktaja Gulma* (uterine fibroids) as in above reported case. Fibroids could be reversed using traditional modalities. Prolonged consumption of traditional organometallic formulations which mainly contain heavy metals may cause renal impairments or nephrotoxicity hence safety concerns cannot be neglected.

ACKNOWLEDGEMENT

We gratefully acknowledge contribution of Mr. D. Y. Mulla, Sub-divisional Officer Water Resources Department, Government of Maharashtra.

CONFLICT OF INTEREST

The authors declare that there is no conflict of interest.

ABBREVIATIONS

ECG: Electrocardiogram; **NSR:** Normal Sinus Rhythm; **BSL:** Blood Sugar Level; **Hb:** Hemoglobin; **NSAIDs:** Nonsteroidal Anti-inflammatory Drugs; **USG:** Ultrasound Sonography; **TmHg:** Thimerosal; **EtHg:** Ethyl-Mercury.

ETHICAL CLEARANCE

Ethical consent from the patient was taken before publication of the data.

REFERENCES

1. Sabry M, Al-Hendy A. Medical treatment of uterine leiomyoma. *Reprod Sci.* 2012; 19(4): 339-53. doi: 10.1177/1933719111432867. Epub 2012. PMID: 22378865; PMCID: PMC3343067.
2. Farris M, Bastianelli C, Rosato E, Brosens I, Benagiano G. Uterine fibroids: an update on current and emerging medical treatment options. *Ther Clin Risk Manag.* 2019; 15: 157-78. doi: 10.2147/TCRM.S147318. PMID: 30774352; PMCID: PMC6350833.
3. Moolamalla S, Bakshi K, Medarametla V. Menstrual Irregularities Post-COVID-19 Infection/Vaccination in Indian Population. *J South Asian Feder Obst Gynae* 2022; 14(6): 694-9.
4. Insha Nazeer, Fathima Muzeera M Musaffar, Fatima A Alsaadi, Maria Hasani, Ambreen Ansar, Tasneem Sandozi. COVID-19 Vaccine-Related Menstrual Disorders among

- Reproductive Age Women in the UAE. *Journal of Women's Health and Development*. 2024; 23-8.
5. Maheen Nazira, Shumaila Asghara, Muhammad Ali Rathoreb, Asima Shahzad, Anum Shahid. Menstrual abnormalities after COVID-19 vaccines: A systematic review. *Vacunas*. 2022; 23(S2):S77-87
 6. Muhaidat N, Alshrouf MA, Azzam MI, Karam AM, Al-Nazer MW, Al-Ani A. Menstrual Symptoms After COVID-19 Vaccine: A Cross-Sectional Investigation in the MENA Region. *Int J Womens Health*. 2022; 14: 395-404. <https://doi.org/10.2147/IJWH.S352167>
 7. Wang, Siwen A prospective study of the association between SARS-CoV-2 infection and COVID-19 vaccination with changes in usual menstrual cycle characteristics. *American Journal of Obstetrics and Gynecology*, 2022; 227(5): 739.e1-739.e11
 8. Baena-García L, Aparicio VA, Molina-López A, Aranda P, Cámara-Roca L, Ocón-Hernández O. Premenstrual and menstrual changes reported after COVID-19 vaccination: The EVA project. *Women's Health*. 2022; 18. doi:10.1177/1745505722112237
 9. Alison Edelman, Emily R Boniface, Victoria Male, Sharon T Cameron, Eleonora Benhar, Leo Han, *et al.* Association between menstrual cycle length and COVID-19 vaccination: global, retrospective cohort study of prospectively collected data: *BMJ Medicine* 2022; 1: e000297.
 10. Victoria Male, COVID-19 vaccination and menstruation *Science*, 2022; 378(6621): 704-6. DOI:10.1126/science.ade1051
 11. Edelman, Alison MD, MPH; Boniface, Emily R. MPH; Benhar, Eleonora PhD; Han, Leo MD, MPH; Matteson, Kristen A. MD, MPH; Favaro, Carlotta PhD; Pearson, Jack T. PhD; Darney, Blair G. PhD, MPH. Association Between Menstrual Cycle Length and Coronavirus Disease 2019 (COVID-19) Vaccination: A U.S. Cohort. *Obstetrics and Gynecology*, 2022; 139(4): 481-9. | DOI: 10.1097/AOG.0000000000004695
 12. De La Cruz MS, Buchanan EM. Uterine Fibroids: Diagnosis and Treatment. *Am Fam Physician*. 2017; 95(2): 100-7. PMID: 28084714.
 13. Alvergne A, Woon EV and Male V. Effect of COVID-19 vaccination on the timing and flow of menstrual periods in two cohorts. *Front. Reprod. Health*. 2022; 4: 952976. doi: 10.3389/frph.2022.952976
 14. Chillon TS, Demircan K, Hackler J, Heller RA, Kaghazian P, Moghaddam A, Schomburg L. Combined copper and zinc deficiency is associated with reduced SARS-CoV-2 immunization response to BNT162b2 vaccination. *Heliyon*. 2023; 9(10): e20919. doi: 10.1016/j.heliyon.2023.e20919. PMID: 37886755; PMCID: PMC10597833.
 15. Khatiban, M. The Positive Effects of Zinc Supplements on the Improvement of Primary Dysmenorrhea and Premenstrual Symptoms: A Double-blind, Randomized, Controlled Trial. *Journal of Midwifery and Reproductive Health*, 2015; 3(3): 378-84. doi: 10.22038/jmrh.2015.4463
 16. Bairwa, K., & Jachak, S. M. Anti-inflammatory potential of a lipid-based formulation of a rotenoid-rich fraction prepared from *Boerhavia diffusa*. *Pharmaceutical Biology*, 2015; 53(8): 1231-8. <https://doi.org/10.3109/13880209.2014.971382>
 17. Pires V, Bramatti I, Aschner M, Branco V and Carvalho C. Thioredoxin Reductase Inhibitors as Potential Antitumors: Mercury Compounds Efficacy in Glioma Cells. *Front. Mol. Biosci*. 2022; 9: 889971. doi: 10.3389/fmolb.2022.889971

Cite this article: Mulla S, Rath B, Wanjari A, Pereira K. Impacts of Traditional Organometallic Interventions on Chronic Uterine Fibroids: A Case Report. *Asian J Biol Life Sci*. 2025;14(2):485-91.